

# Advanced hepatocellular carcinoma with portal tumor thrombosis in cirrhotic patient: laparoscopic right hepatectomy with vascular reconstruction

Rodrigo Canada Surjan<sup>1</sup>, Fabio Ferrari Makdissi<sup>2</sup>, Tiago Basseres<sup>1</sup>, Marcel Autran Cesar Machado<sup>1</sup>

<sup>1</sup>Surgery Department, <sup>2</sup>Gastrointestinal Surgery Department, University of São Paulo, Medical School, São Paulo, Brazil

Correspondence to: Rodrigo Canada Surjan, MD, PhD. Surgery Department, University of São Paulo, Medical School, Rua Michigan 470, Torre 1, apt 203, Brooklin Novo, São Paulo, SP, Brazil. Email: rodrigo.surjan@gmail.com.

**Abstract:** Hepatocellular carcinoma (HCC) is the commonest hepatic malignancy and is frequently associated with cirrhosis and vascular involvement. Liver resection (LR) is a potentially curative treatment to HCC, but is a challenging task in cirrhotic patients especially with tumor vascular invasion. The laparoscopic approach is associated with lower morbidity rates in cirrhotic patients, but is rarely reported in cases of involvement of the portal vein. We report a laparoscopic right hepatectomy with portal vein reconstruction in a cirrhotic HCC patient with advanced portal vein tumor thrombosis. This is a potentially curative and complex procedure that can be an effective technique in highly selected patients that usually would be considered only for palliative systemic treatment.

**Keywords:** Liver; hepatectomy; laparoscopy; carcinoma; hepatocellular

Received: 28 September 2018; Accepted: 12 October 2018; Published: 26 October 2018.

doi: 10.21037/jovs.2018.10.16

View this article at: <http://dx.doi.org/10.21037/jovs.2018.10.16>

## Introduction

Hepatocellular carcinoma (HCC) is the most frequent primary hepatic malignancy and is frequently associated with cirrhosis (1). Tumor vascular invasion may be present in many cases of HCC. Although it is associated with poor prognosis, liver resection (LR) may result in improved long-term survival when compared to other therapies (2).

Performing a hepatectomy in a HCC patient with cirrhosis is a challenging task due to the risk of postoperative liver failure and increased morbidity and mortality rates (3). Laparoscopic liver resections (LLR) emerged as an alternative as it allows lower postoperative liver failure and morbidity rates, and has been widely adopted (3-5).

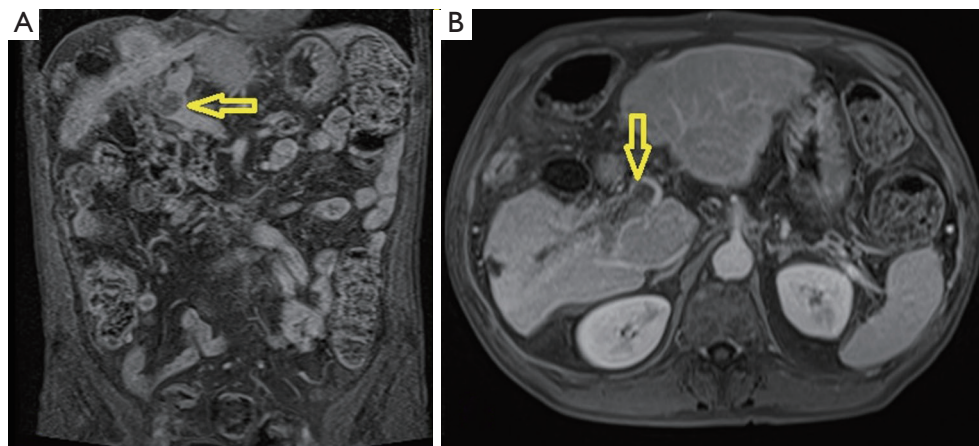
However, there are very few reported cases of LLR in cases of portal vein tumor thrombosis because of the technical challenges and risk of postoperative complications involved (6).

## Case presentation

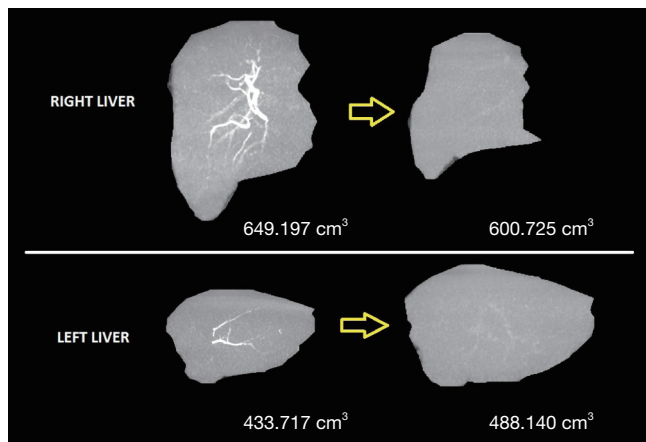
### *Patient and pre-operative work-up*

A 72-year-old male with alcoholic cirrhosis presented with upper abdominal pain in the last 2 weeks. A magnetic resonance image (MRI) study disclosed a 10 cm lesion suggestive of HCC on the right hepatic lobe with tumor thrombosis of the right portal vein (*Figure 1*). Total hepatic volume was 1,083 mL and the left liver (the future remnant liver) presented 433.8 mL. As symptoms lasted for only 2 weeks, we assumed that the right portal vein thrombosis was recent (left liver hypertrophy could happen), and taking under consideration the high mortality rates of a right hepatectomy on a cirrhotic patient, initial treatment was chemotherapy with sorafenib.

One month after sorafenib was started a computed tomography (CT-scan) was performed. HCC dimensions persisted but areas of necrosis appeared. Due to right portal



**Figure 1** MRI study disclosing a 10 cm HCC with tumor thrombosis of the right portal vein and partial involvement of the main portal trunk (yellow arrows). (A) Coronal plane; (B) axial plane. MRI, magnetic resonance image; HCC, hepatocellular carcinoma.



**Figure 2** CT-scan with hepatic volumetry performed one month after sorafenib (45 days after initial symptoms) disclosing a 13% increase in left liver volume and a 7,5% reduction in right liver volume. CT-scan, computed tomography scan.

vein thrombosis, left liver increased from 433.8 to 488 mL (13%) and the right liver (resected on a right hepatectomy) reduced from 649.2 to 600.8 mL (7.5%) (Figure 2).

As the liver showed signs of regenerative capacity, a laparoscopic right hepatectomy with portal vein thrombectomy and reconstruction was proposed.

#### *Pre-operative preparation*

As pre-operative preparation an electrocardiography, an echocardiogram and laboratory tests including liver

function tests were performed.

#### *Equipment preference card*

The endoscopic materials used for the procedure were: a 30-degree, 10-mm endoscope (Storz. Tuttlingen, Germany), the SDC Ultra HD Information Image Management System Endoscopy (Stryker. Kalamazoo, USA), 1288 HD High definition Camera (Stryker, Kalamazoo, USA), L9000 Led Light Source (Stryker. Kalamazoo, USA), and Penumo Sure High Flow Insuflator (Stryker, Kalamazoo, USA). The harmonic scalpel used was the Ultracision Harmonic Ace® (Ethicon. Somerville, USA) and we used the Echelon Flex™ Endopath® Stapler (Ethicon. Somerville, USA).

#### *Procedure*

Two 12 mm and three 5 mm trocars were used (Figure 3). At inspection there were signs of portal hypertension and cirrhosis and the right liver was atrophied (Figure 4A). The right hepatic artery and bile duct were transected. Then, the main portal vein was dissected close to its bifurcation and encircled. After some parenchymal transection, we proceeded to the treatment of the portal vein tumor thrombosis. Instead of performing a left hemi-Pringle, we performed an isolated clamping of the left portal vein leaving the left hepatic artery open to lessen remnant liver warm ischemia. Then, the main portal vein was clamped (Figure 4B). The right portal vein and a lateral portion of the main portal vein were transected.

Tumor thrombectomy of the main portal vein was performed (Figure 4C). A running suture was run up the defect created (Figure 4D). Clamps were removed. Then, parenchymal transection was performed in the plane correspondent to a right hepatectomy. The right hepatic vein was transected with an endoscopic stapler. Specimen was retracted through a suprapubic incision. A Blake drain was put in place and the procedure completed.

Operative time was 500 minutes. Estimated blood loss

was 275 milliliters (Figure 5).

### Role of team members

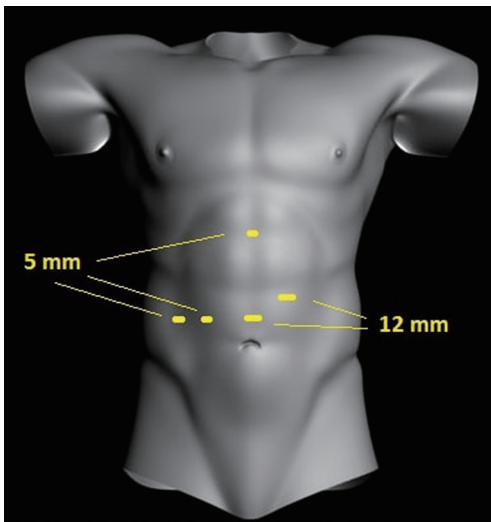
The team consisted of four gastrointestinal surgeons with expertise in hepato-bilio-pancreatic surgery and an anesthesiologist. One surgeon performed all the steps of the procedure. Another surgeon was the camera assistant during the entire procedure and the other two surgeons were assistants.

### Post-operative management

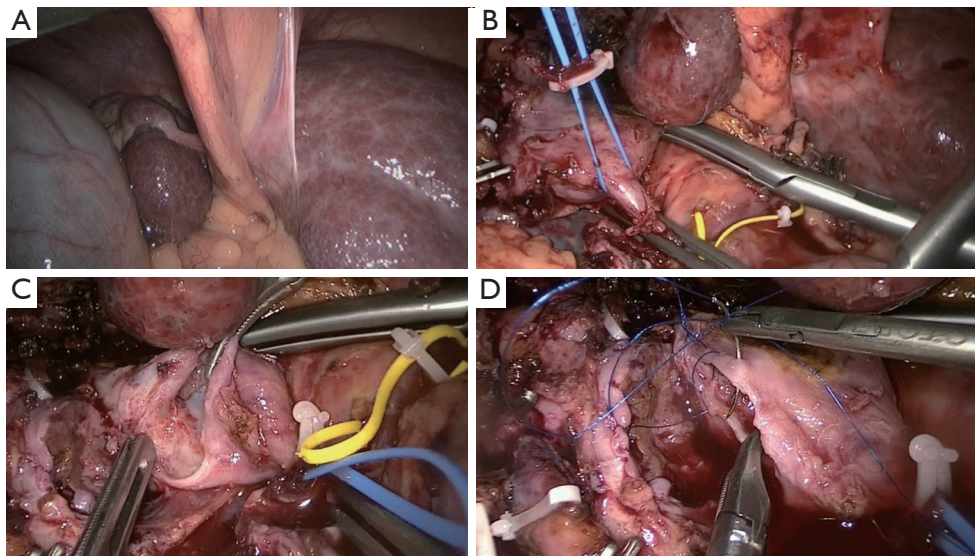
Patient developed mild ascites, managed with diuretics for one month. He presented no other signs of liver dysfunction. He stayed on the intensive care unit for two days and was discharged from hospital on postoperative day 10. A CT scan was performed one week after the surgery and disclosed normal portal vein flow. Pathology came out as high degree HCC with vascular invasion. Margins were free from tumor. One year after a CT-scan showed no signs of tumor recurrence.

### Discussion

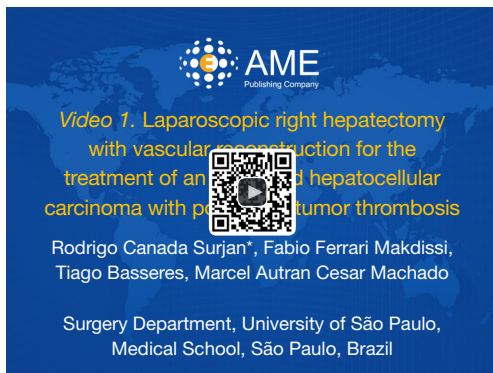HCC is the fifth most common malignancy in the world and ranks third in cancer-related deaths (8). During the



**Figure 3** Trocar displacement.



**Figure 4** Intraoperative images. (A) Recanalized umbilical vein, signs of chronic hepatic disease and right liver partially atrophied; (B) left portal vein and the main portal vein trunk clamped; (C) main portal vein opening after tumor thrombectomy; (IV) suture of the portal vein.



**Figure 5** Laparoscopic right hepatectomy with vascular reconstruction for the treatment of an advanced hepatocellular carcinoma with portal vein tumor thrombosis (7).

Available online: <http://www.asvide.com/article/view/27882>

last few decades multiple therapeutic modalities for the treatment of HCC have emerged, such as locoregional therapies (ablation, embolization, chemoembolization, and percutaneous alcohol injection), external beam radiation and systemic therapies, but surgical resection remains the only potentially curative treatment modality (9-12).

LRs should be considered in patients that are not eligible for transplantation not only in patients without chronic hepatic disease but also in HCC patients with cirrhosis if hepatic function is expected to tolerate partial parenchymal resection (13). Although the best oncological results from LR seem to come from the resection of small tumors, tumor size (even for those lesions larger than 10 cm) is not any longer indicative of resectability (14). Despite the fact that large HCC are associated with high incidence of vascular invasion, even large and locally advanced HCC with portal involvement seem to benefit from major LR (13,14).

Since 1991 when Reich *et al.* reported the LLR of benign liver tumors and Gagner *et al.* performed the first laparoscopic complex hepatectomy in 1992, growing experience and development in surgical techniques resulted in widespread application of laparoscopic hepatectomies even to the treatment of HCC (15,16). Nowadays, the indications LLR are almost equal to the open approach (17).

For many years, LLR for HCC were not very popular due to concerns related to tumor seeding, possibility of metastasis to trocar incisions, resection margins and long-term survival (18). However, various meta-analyses demonstrated that LLR for HCC are safe procedures with the potential advantages of lower operative blood loss, lower blood transfusion requirement and lower postoperative

hospital length of stay and tumor recurrence compared to open hepatectomies (19,20). In cirrhotic patients, LLR have the further advantages of lower postoperative ascites formation and risk of liver failure (21).

We presented a case that would usually be candidate only for palliative systemic treatment. The patient presented with portal hypertension and cirrhosis, large HCC that would not normally benefit from locoregional therapies, portal involvement and the necessity of major hepatic resection that usually precludes surgical treatment. As a result of adequate preoperative planning, accurate laparoscopic techniques and careful postoperative care, we performed a major LR that resulted in prolonged survival in a case that, otherwise, would probably have limited survival after the initial diagnosis.

### Acknowledgements

None.

### Footnote

*Conflicts of Interest:* The authors have no conflicts of interest to declare.

*Informed Consent:* Written informed consent was obtained from the patient for publication of this manuscript and any accompanying images.

### References

1. Fattovich G, Stroffolini T, Zagni I, et al. Hepatocellular carcinoma in cirrhosis: incidence and risk factors. *Gastroenterology* 2004;127:S35-50.
2. Xiao CZ, Wei W, Guo ZX, et al. A prognosis model for patients with hepatocellular carcinoma and portal vein tumor thrombus following hepatic resection. *Oncol Lett* 2015;10:2787-94.
3. Belli A, Cioffi L, Russo G, et al. Liver resection for hepatocellular carcinoma in patients with portal hypertension: the role of laparoscopy. *Hepatobiliary Surg Nutr* 2015;4:417-21.
4. Cherqui D, Laurent A, Tayar C, et al. Laparoscopic liver resection for peripheral hepatocellular carcinoma in patients with chronic liver disease: midterm results and perspectives. *Ann Surg* 2006;243:499-506.
5. Cheung TT, Lo CM. Laparoscopic liver resection for hepatocellular carcinoma in patients with cirrhosis.

- Hepatobiliary Surg Nutr 2015;4:406-10.
6. Nakahira S, Takeda Y, Katsura Y, et al. Laparoscopic left hepatectomy with tumor thrombectomy in patients with hepatocellular carcinoma concomitant with advanced portal vein tumor thrombus. *Surg Endosc* 2014;28:3505.
  7. Surjan RC, Makdissi FF, Basseres T, et al. Laparoscopic right hepatectomy with vascular reconstruction for the treatment of an advanced hepatocellular carcinoma with portal vein tumor thrombosis. *Asvide* 2018;5:818. Available online: <http://www.asvide.com/article/view/27882>
  8. Yeh MM, Yeung RS, Apisarnthanarax S, et al. Multidisciplinary perspective of hepatocellular carcinoma: A Pacific Northwest experience. *World J Hepatol* 2015;7:1460-83.
  9. Huang J, Yan L, Cheng Z, et al. A randomized trial comparing radiofrequency ablation and surgical resection for HCC conforming to the Milan criteria. *Ann Surg* 2010;252:903-12.
  10. Brown DB, Gould JE, Gervais DA, et al. Transcatheter therapy for hepatic malignancy: standardization of terminology and reporting criteria. *J Vasc Interv Radiol* 2009;20:S425-34.
  11. Chino F, Stephens SJ, Choi SS, et al. The role of external beam radiotherapy in the treatment of hepatocellular cancer. *Cancer* 2018;124:3476-89.
  12. Llovet JM, Ricci S, Mazzaferro V, et al. Sorafenib in advanced hepatocellular carcinoma. *N Engl J Med* 2008;359:378-90.
  13. Korean Liver Cancer Study Group (KLCSG); National Cancer Center, Korea (NCC). 2014 Korean Liver Cancer Study Group-National Cancer Center Korea Practice Guideline for the Management of Hepatocellular Carcinoma. *Korean J Radiol* 2015;16:465-522.
  14. Lee SG, Hwang S, Jung JP, et al. Outcome of patients with huge hepatocellular carcinoma after primary resection and treatment of recurrent lesions. *Br J Surg* 2007;94:320-6.
  15. Gagner M, Rheault M, Dubuc J. Laparoscopic partial hepatectomy for liver tumor. *Surg Endosc* 1992;6:97-8.
  16. Machairas N, Papaconstantinou D, Stamopoulos P, et al. The Emerging Role of Laparoscopic Liver Resection in the Treatment of Recurrent Hepatocellular Carcinoma: A Systematic Review. *Anticancer Res* 2018;38:3181-6.
  17. Cai X. Laparoscopic liver resection: the current status and the future. *Hepatobiliary Surg Nutr* 2018;7:98-104.
  18. Lai EC, Tang CN, Ha JP, et al. Laparoscopic liver resection for hepatocellular carcinoma: ten-year experience in a single center. *Arch Surg* 2009;144:143-7.
  19. Li N, Wu YR, Wu B, et al. Surgical and oncologic outcomes following laparoscopic versus open liver resection for hepatocellular carcinoma: A meta-analysis. *Hepatol Res* 2012;42:51-9.
  20. Xiong JJ, Altaf K, Javed MA, et al. Meta-analysis of laparoscopic vs open liver resection for hepatocellular carcinoma. *World J Gastroenterol* 2012;18:6657-68.
  21. Belli G, Fantini C, D'Agostino A, et al. Laparoscopic versus open liver resection for hepatocellular carcinoma in patients with histologically proven cirrhosis: short- and middle-term results. *Surg Endosc* 2007;21:2004-11.

doi: 10.21037/jovs.2018.10.16

**Cite this article as:** Surjan RC, Makdissi FF, Basseres T, Machado MA. Advanced hepatocellular carcinoma with portal tumor thrombosis in cirrhotic patient: laparoscopic right hepatectomy with vascular reconstruction. *J Vis Surg* 2018;4:223.